Ultrasound Guided Regional Anesthesia

Upper Extremity Blocks

Upper Extremity Regional Blocks

- Interscalene
- Supraclavicular
- Infraclavicular
- Axillary
- Musculocutaneous
- Median and Ulnar

Objectives

- Indications
- Anatomy
- Ultrasound Technique
- Ultrasound Landmarks

Brachial Plexus Levels

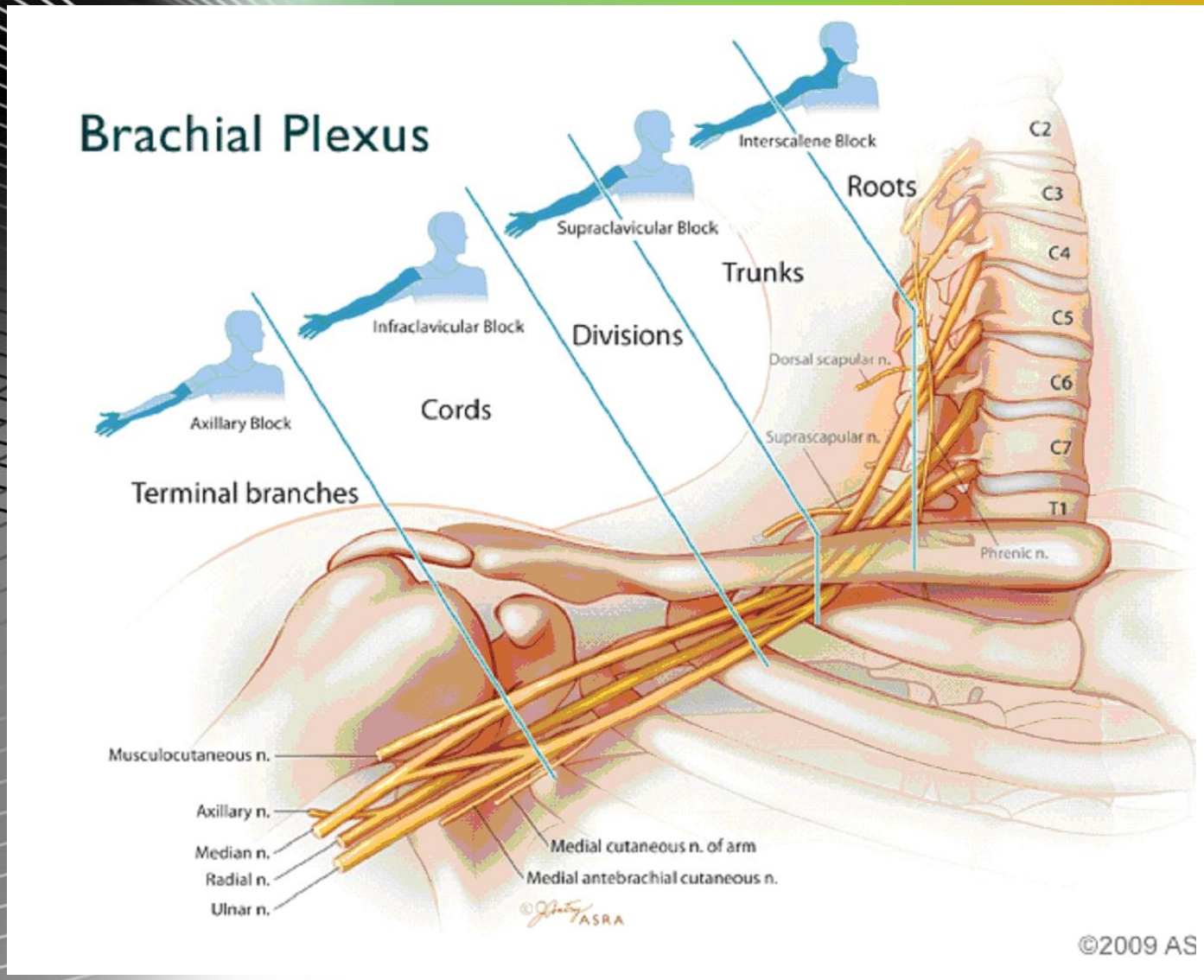

Upper Extremity Anatomy

Brachial Plexus

- Interscalene
- Supraclavicular
- Infraclavicular
- Axillary

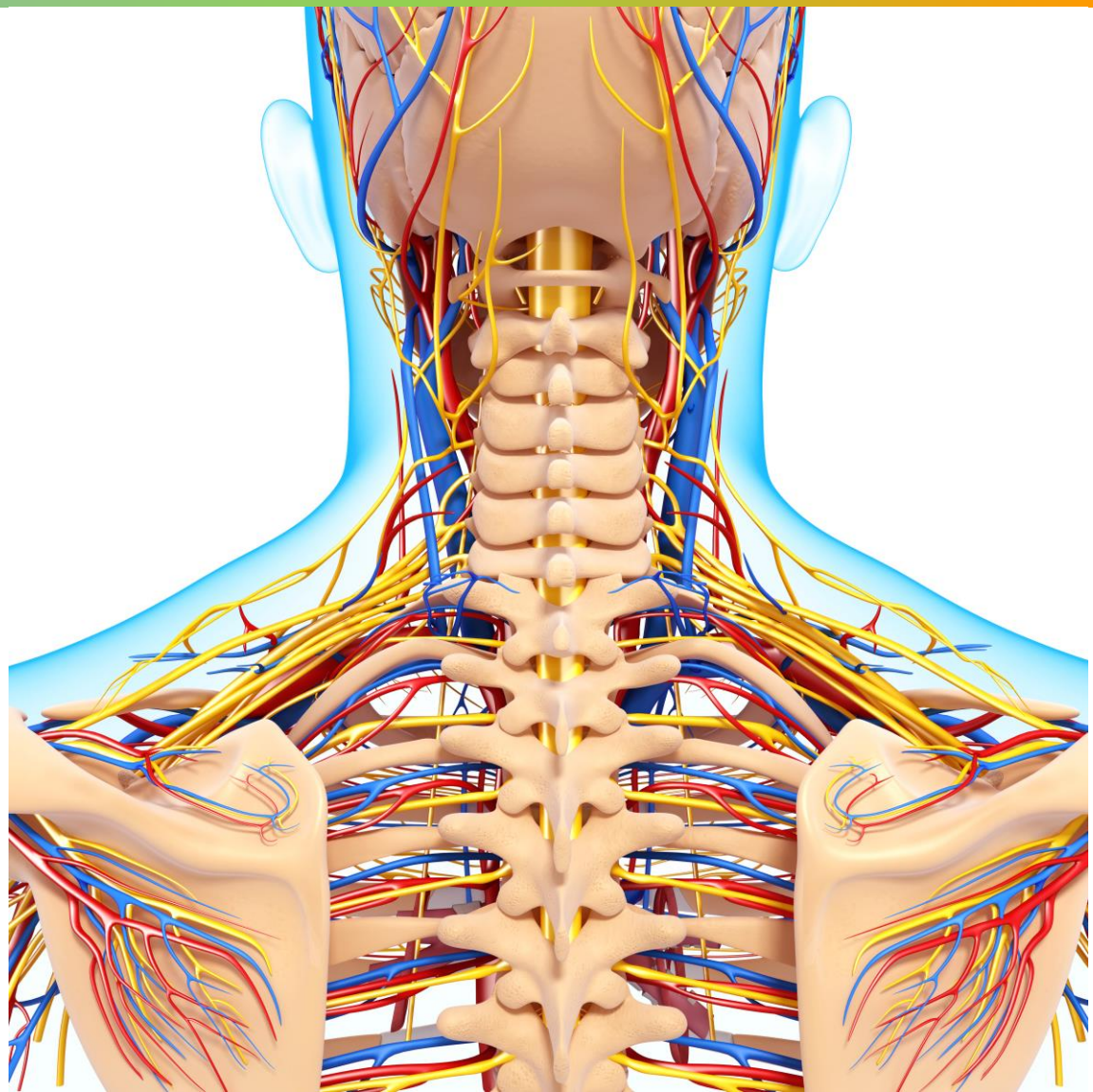

Interscalene Block

Indications

- shoulder and upper arm surgery

Goal

- anesthesia around superior and middle trunks of brachial plexus between anterior and middle scalene muscles

Technique: In-plane or out of plane

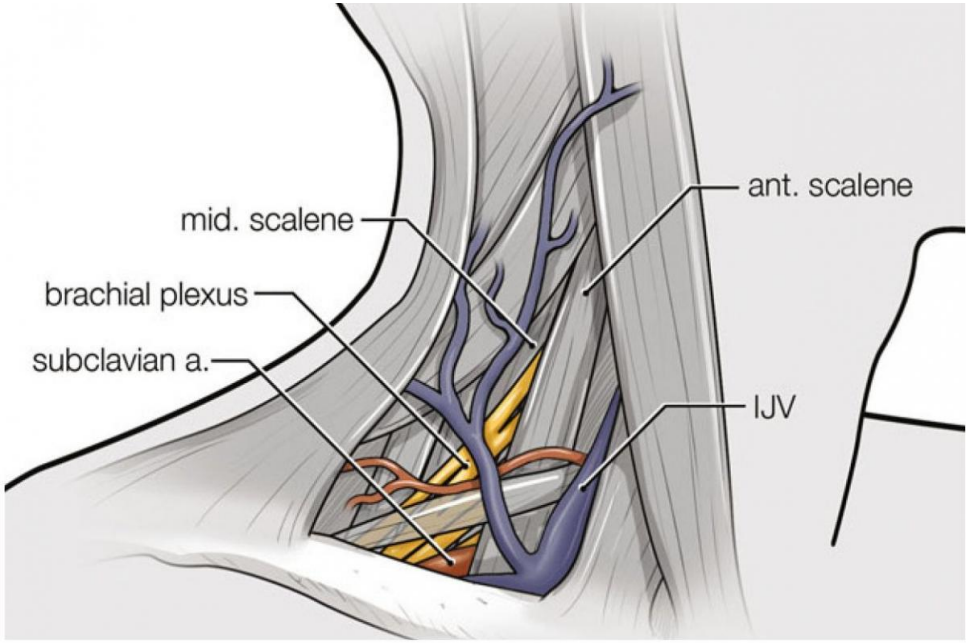

Interscalene Transducer Placement

Patient is positioned in a 45 degree reclining position
Begin by identifying supraclavicular region of brachial plexus as landmark then slide up neck to interscalene groove
Orientation marker to right at 3:00 position.

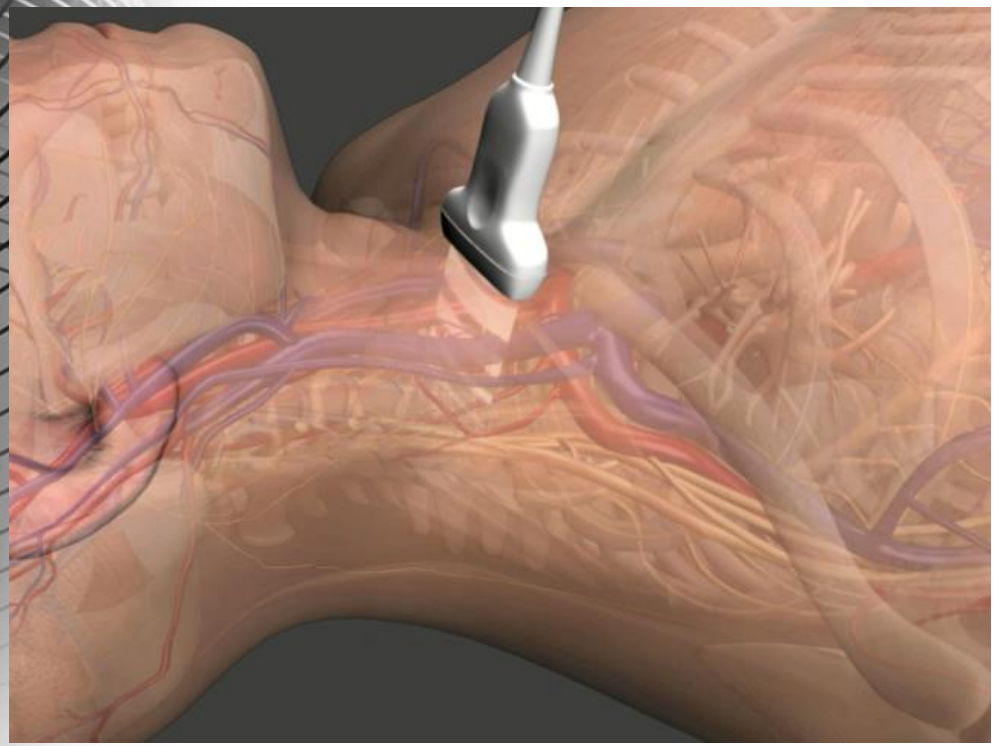

Interscalene Level: Transducer Position

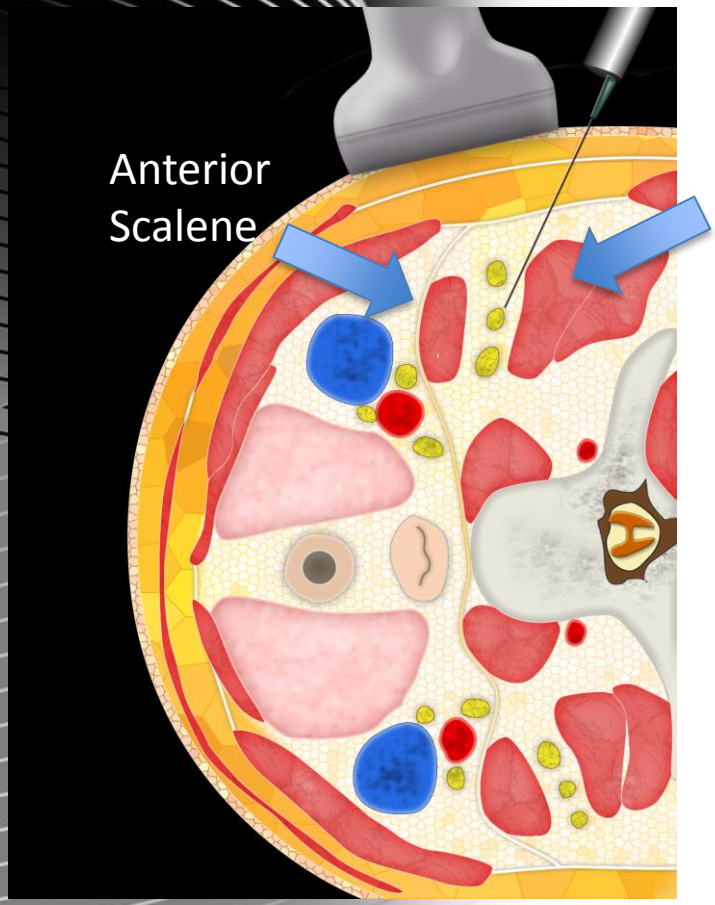

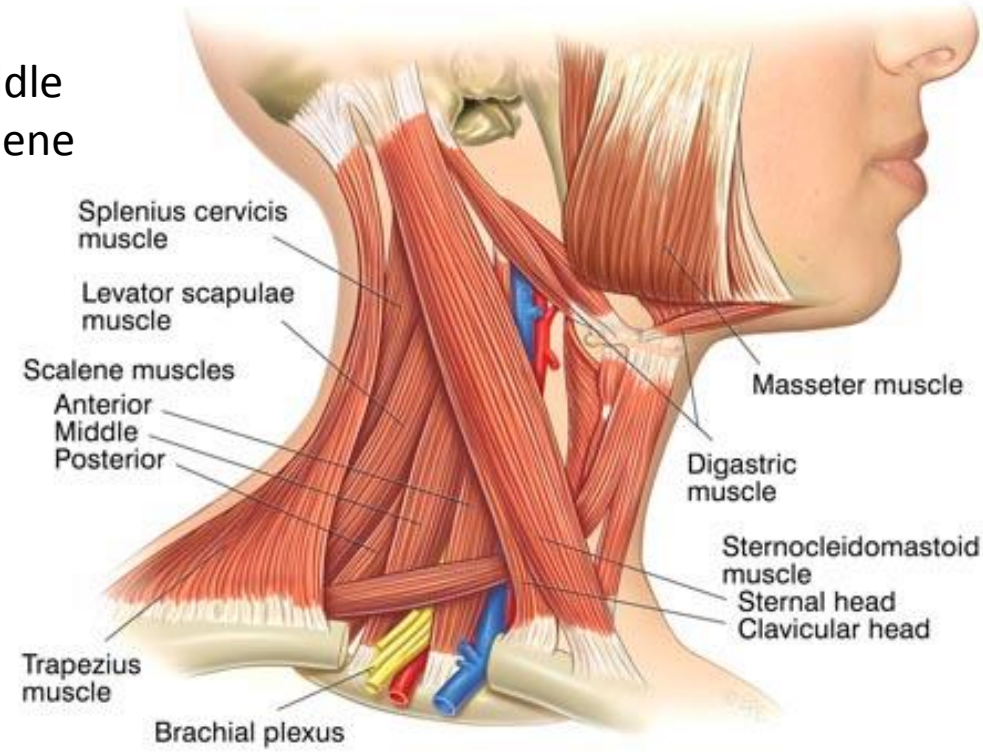

Ultrasound Image Brachial Plexus

Nerves will change in shape from a grape like cluster in the supraclavicular region to a chain link appearance in the interscalene groove.

C5 and C6 nerve roots appear as 3 circles

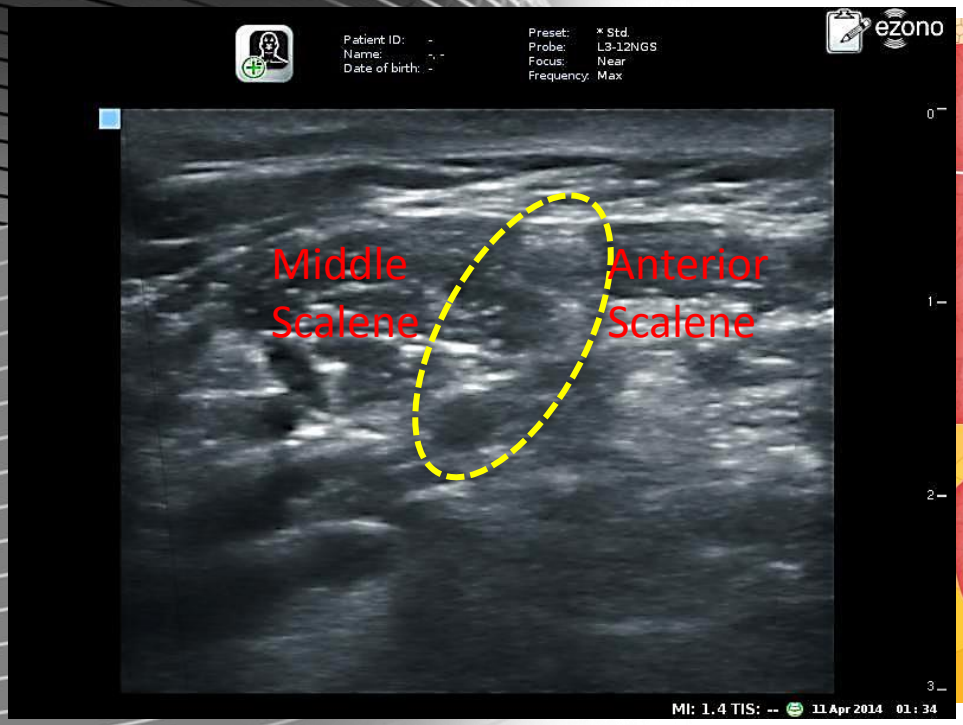

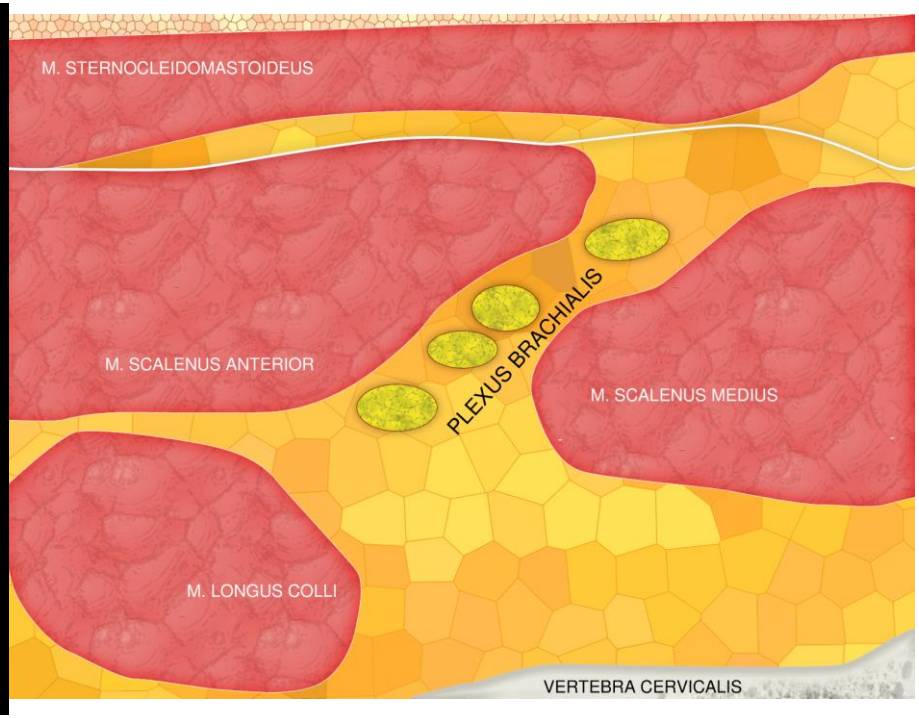

Supraclavicular Block

- Indications: Arm, elbow, forearm, hand surgery
- Goal: Anesthetic around brachial plexus lateral and superficial to subclavian artery
- Technique: In-plane
- Gold Standard: Results in anesthesia of the upper limb below the shoulder because trunks and divisions are included with this block
- Challenge: Close proximity to subclavian artery and lung

Supraclavicular: Trunks

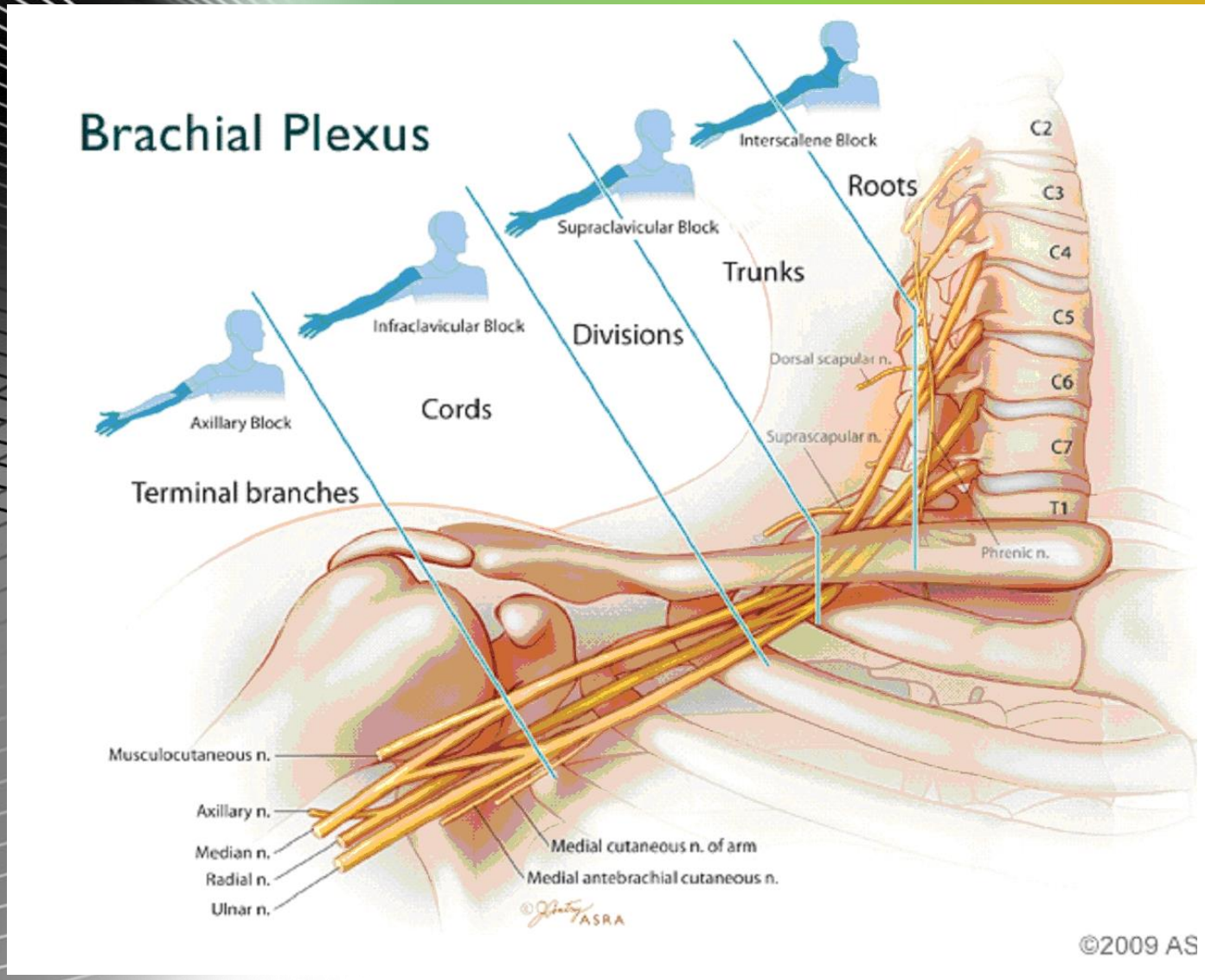

Supraclavicular Landmarks

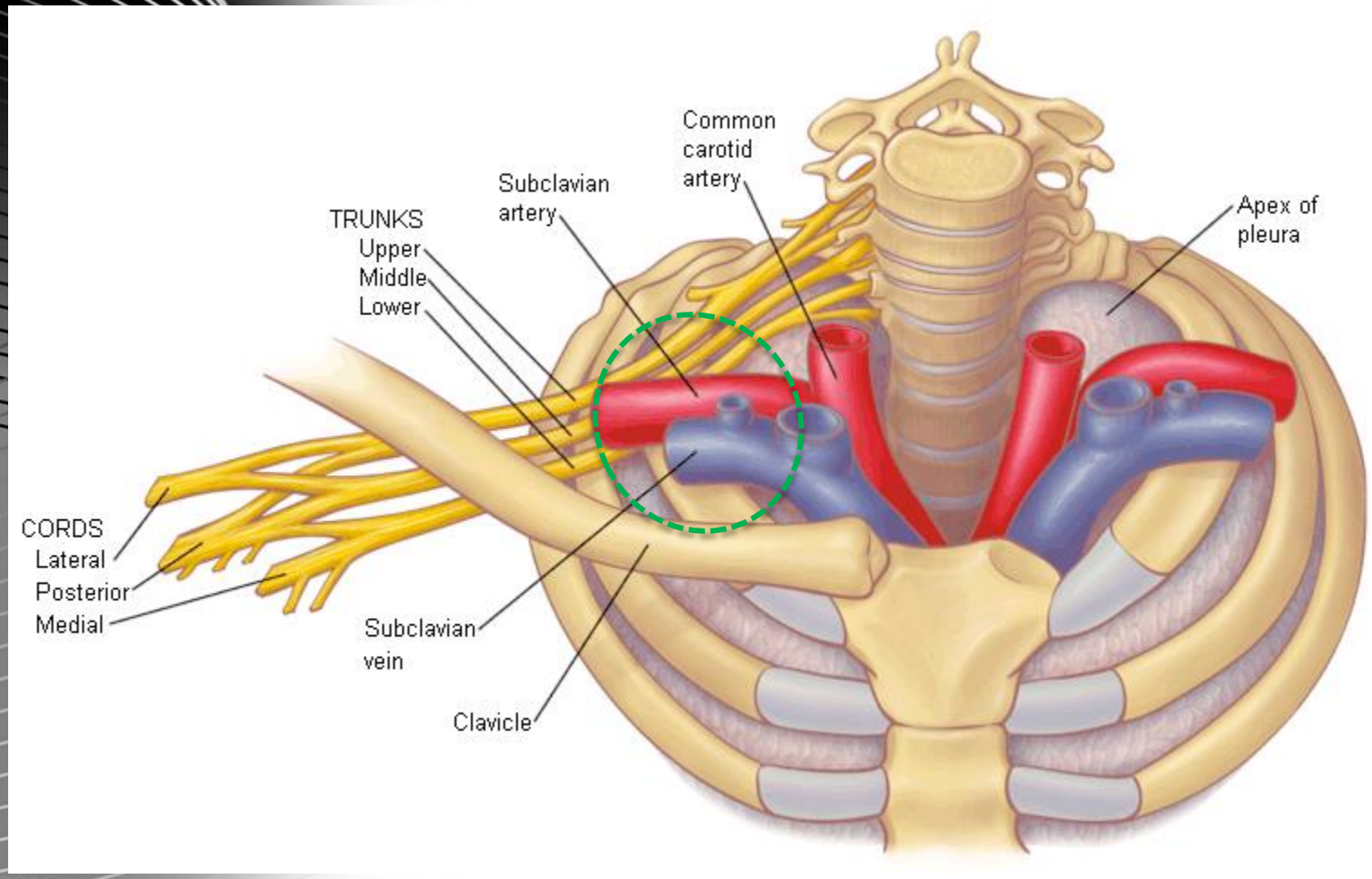

Transducer Position

Patient position 45 degree reclining
Transducer midpoint clavicle at an acute angle aimed into thorax
Orientation marker patient's right at a 10:00

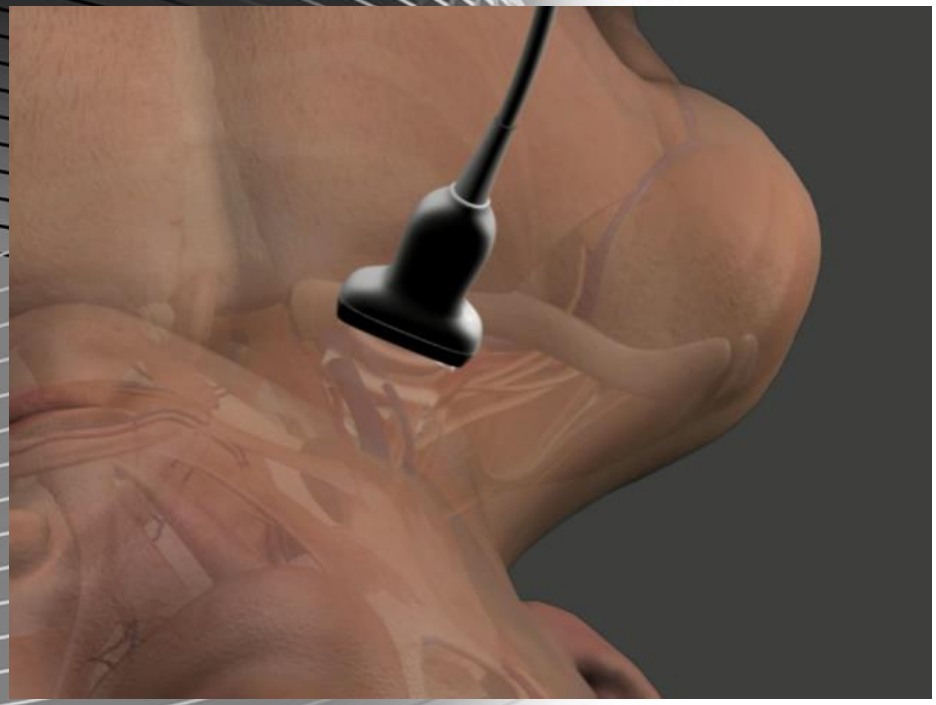

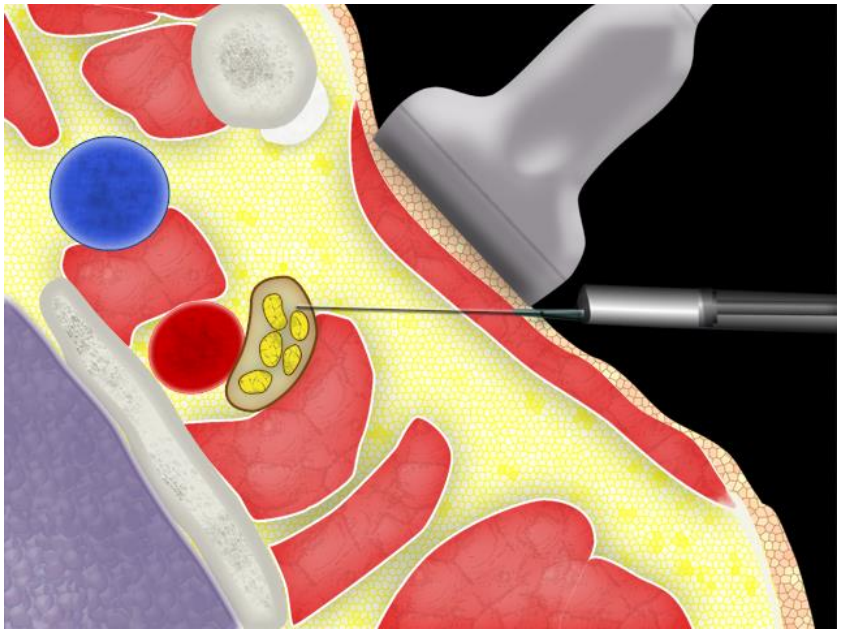

Ultrasound Supraclavicular

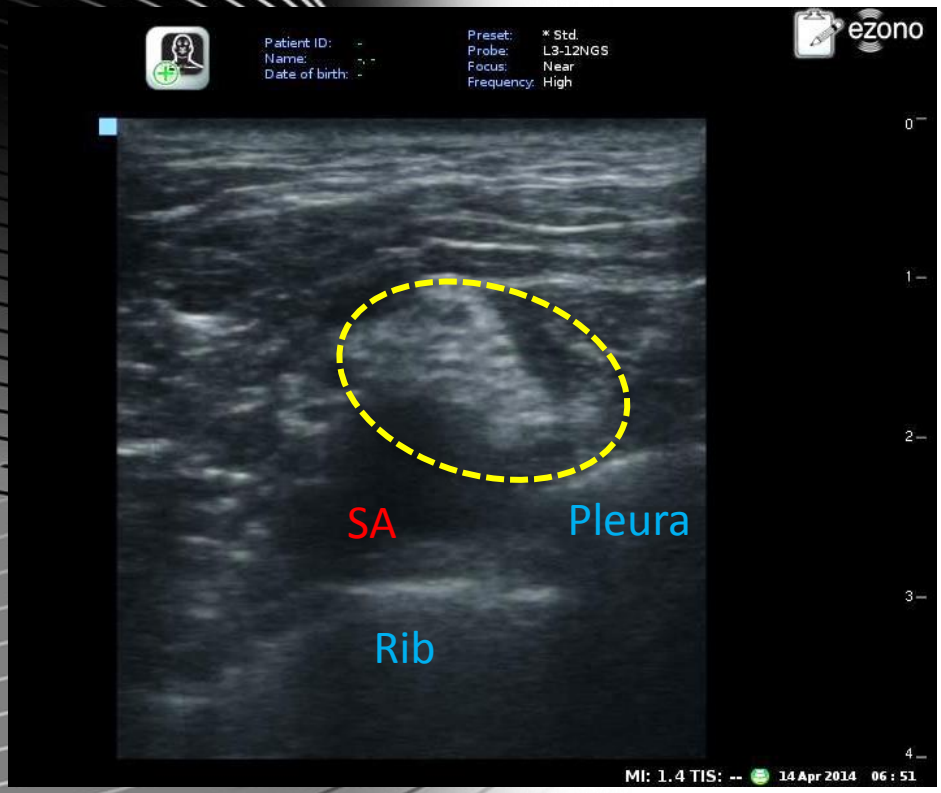

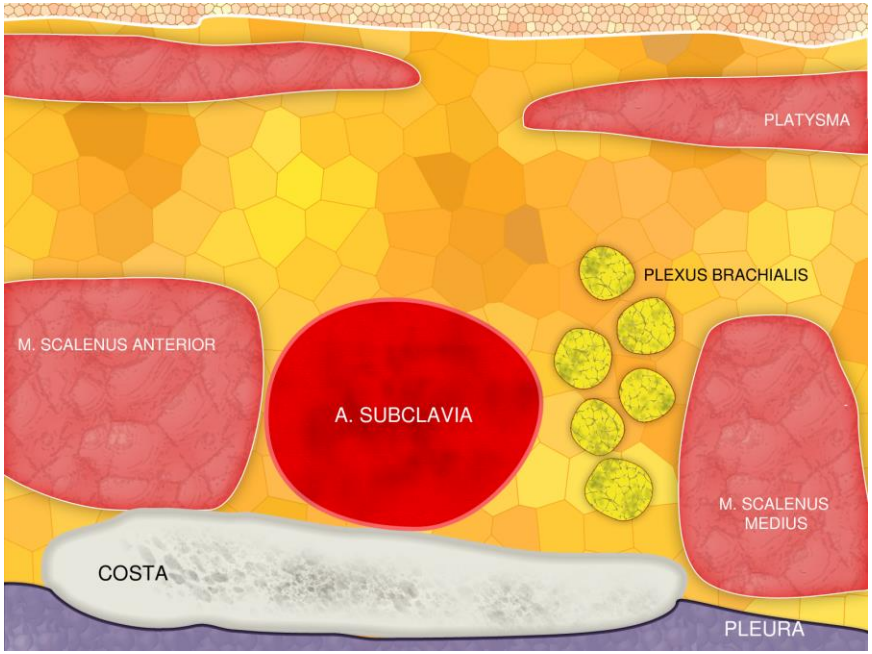

Nerve trunks are posterior or superior to the subclavian artery.
Nerve trunks are hypoechoic dark circles within bright hyperechoic fascia of brachial plexus.
It is important to distinguish the pleura from the first rib to avoid a pneumothorax.

Transducer Position

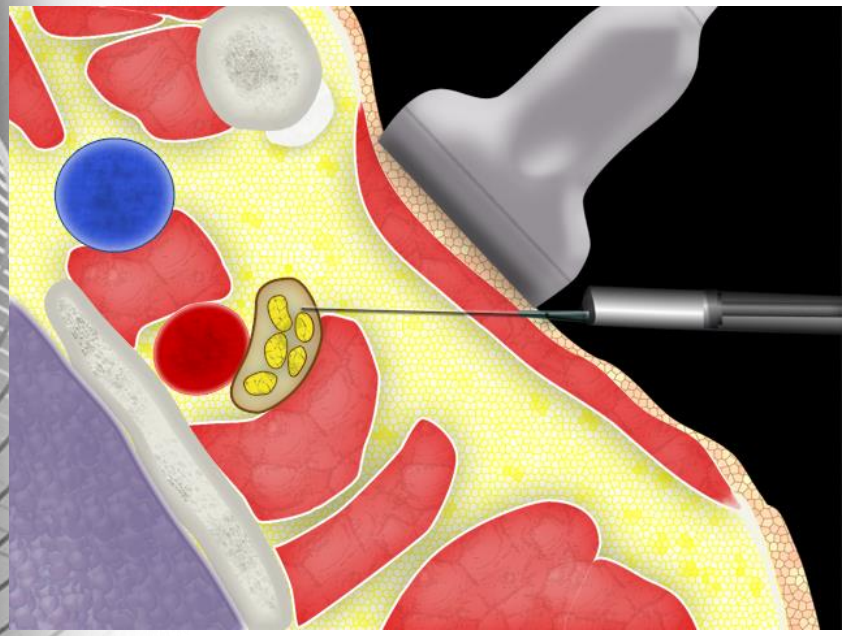

In-plane technique - needle 1 to 2 cm lateral to transducer
Initial end point of the needle is just posterior to the artery immediately above the first rib.

Infraclavicular Block

- Indications: Arm, elbow, forearm, hand surgery
- Goal: Anesthetic spread around axillary artery to reach medial, posterior, lateral cords
- Technique: In-plane

Infraclavicular: Cords

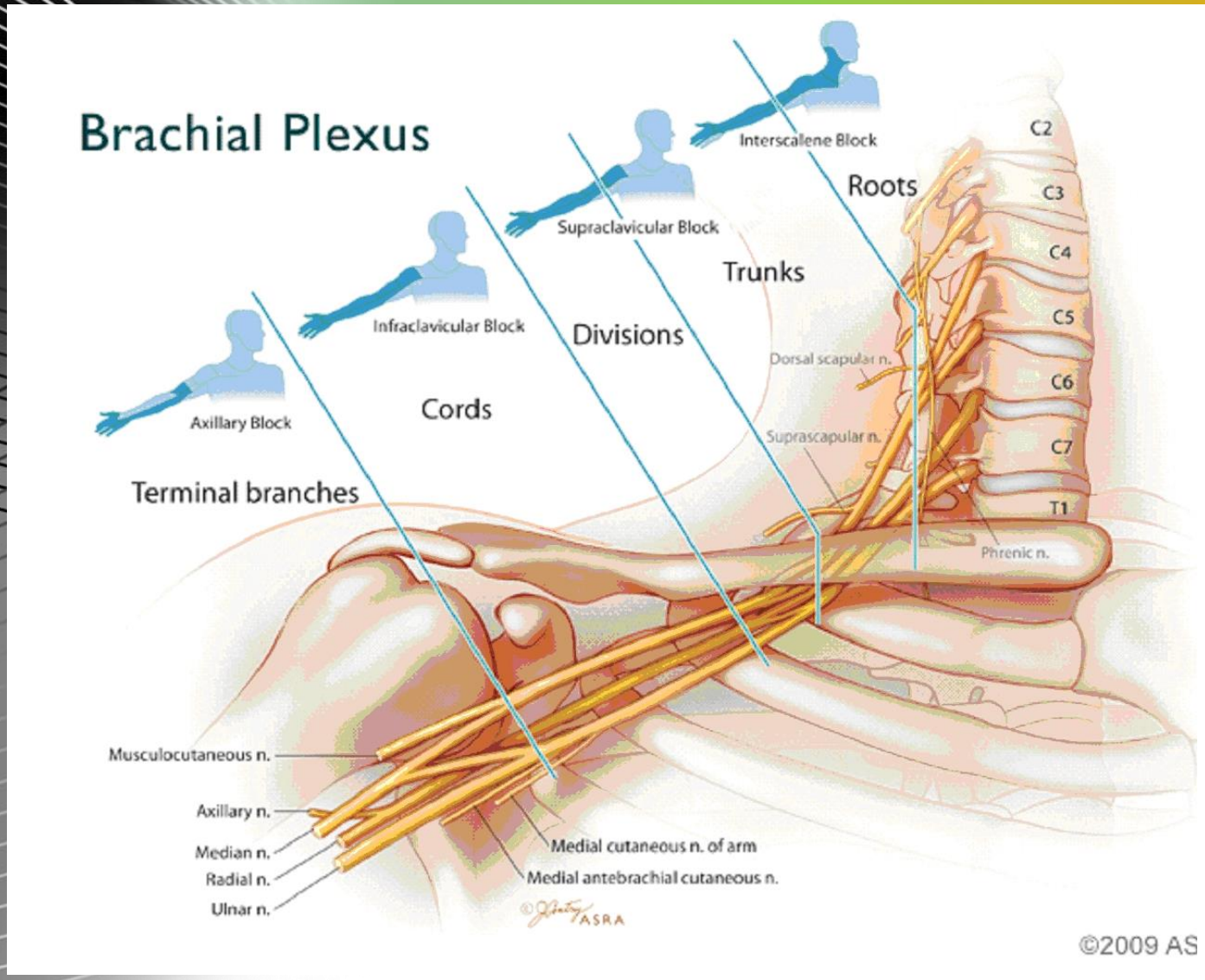

Anatomy Infraclavicular Block

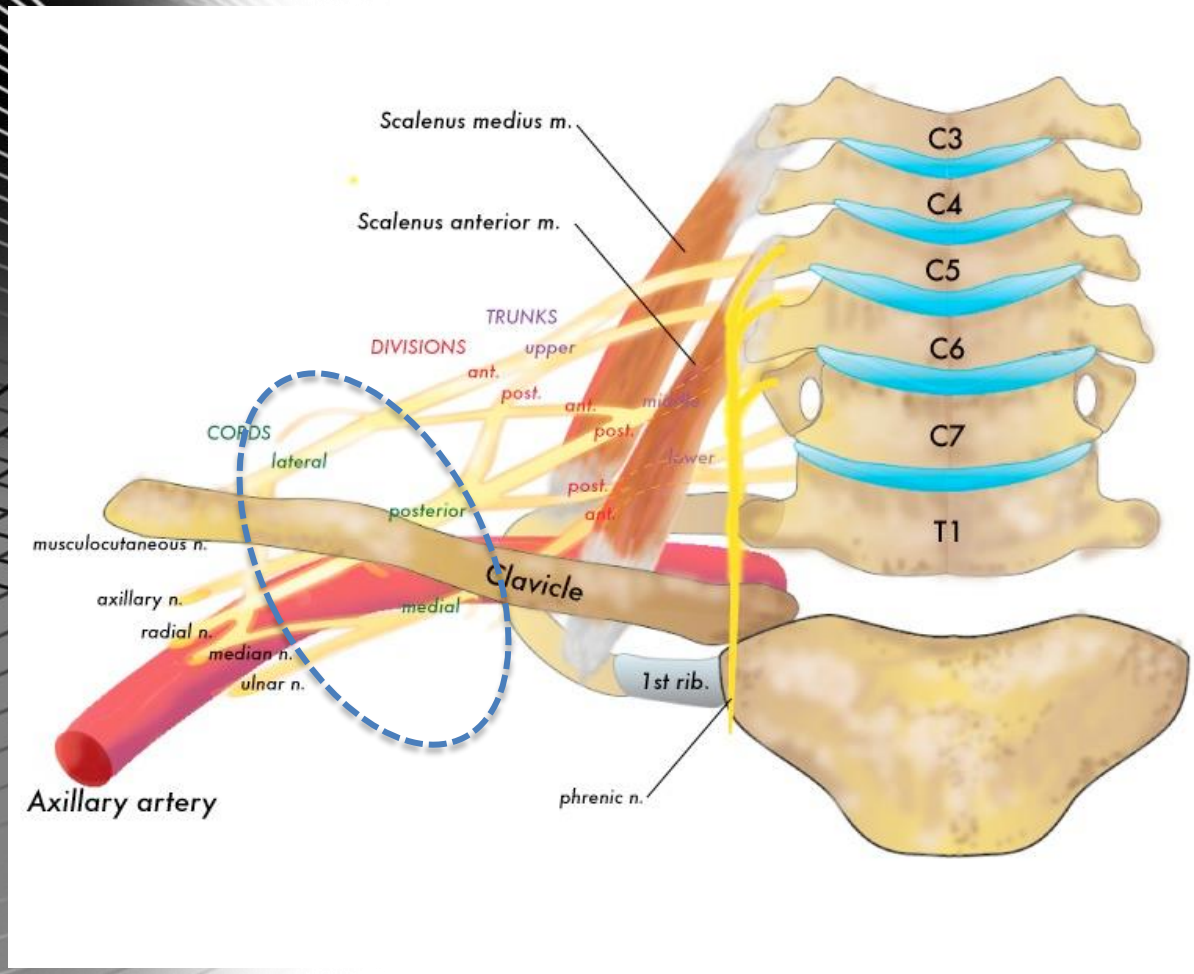

Infraclavicular Transducer Position

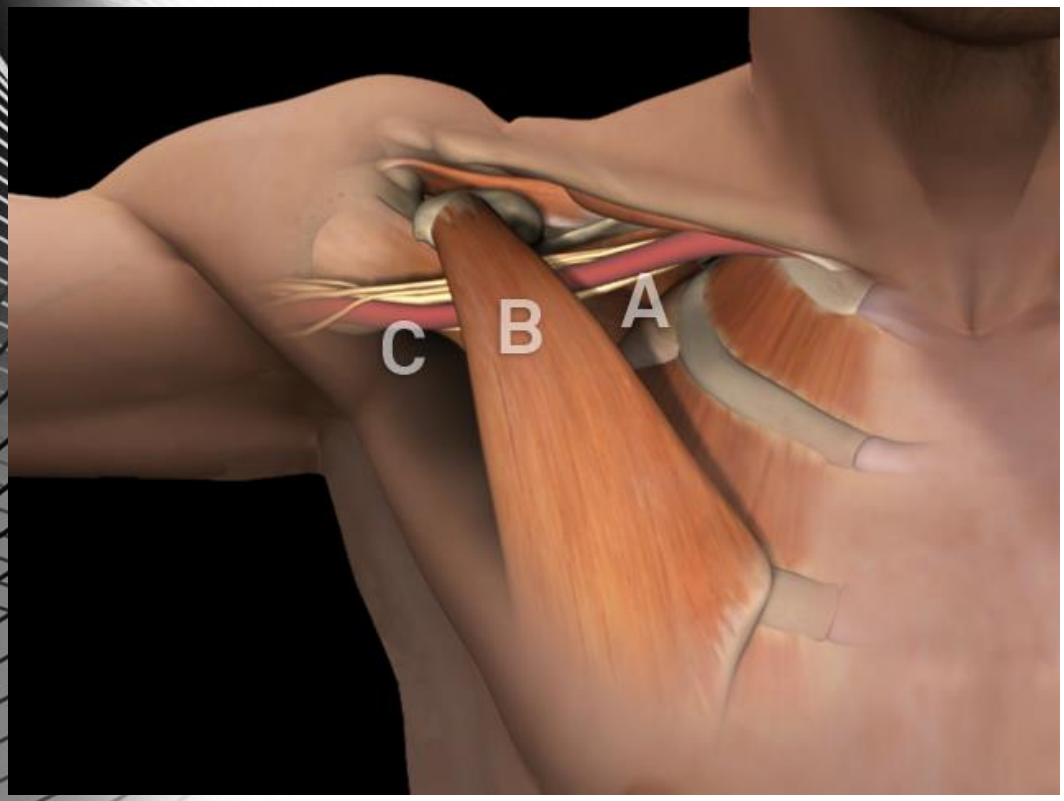

The patient supine with arm abducted 90 degrees and elbow bent 90 degrees to move the clavicle posterior and permit a shallow angle of needle insertion.

Infraclavicular Transducer Position

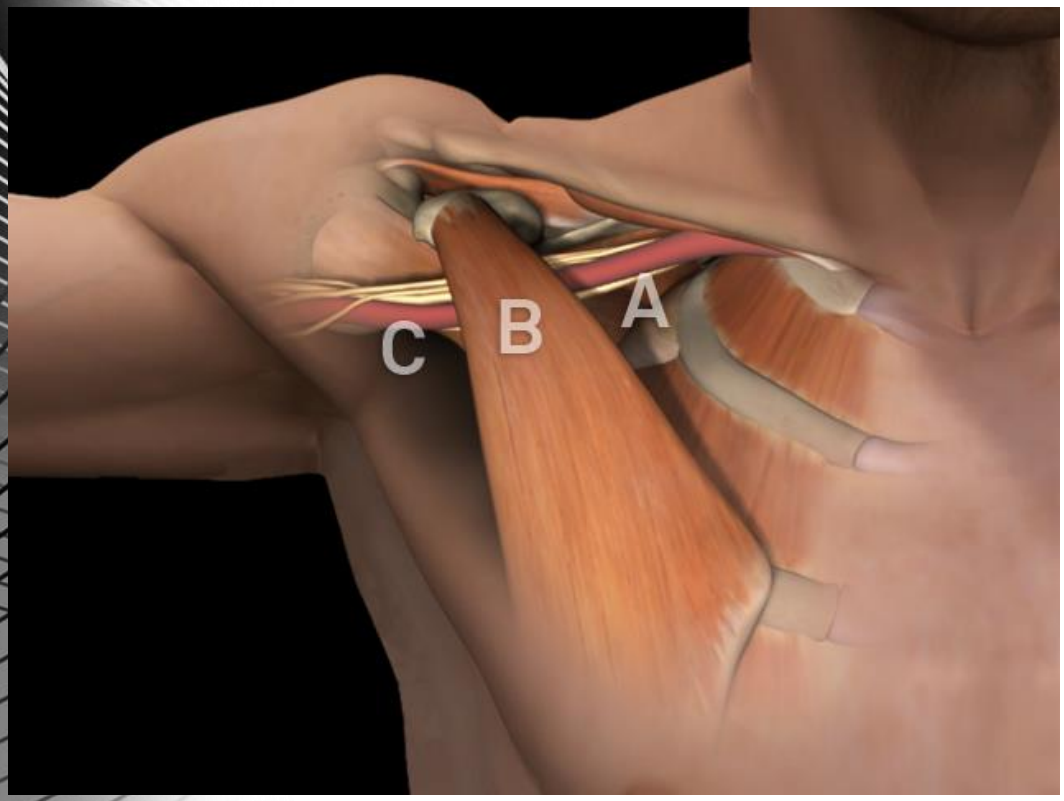

Transducer slowly moved laterally to follow axillary artery.
Nerves will split into lateral, medial, and posterior cords. The optimum position for the infraclavicular nerve block is as lateral as possible.

Infraclavicular Transducer Position

In plane technique needle positioned 2cm cephalad to transducer
Needle path is directed over the clavicle and through pectoral muscles.
Initial end point for needle is posterior to the midpoint of the artery

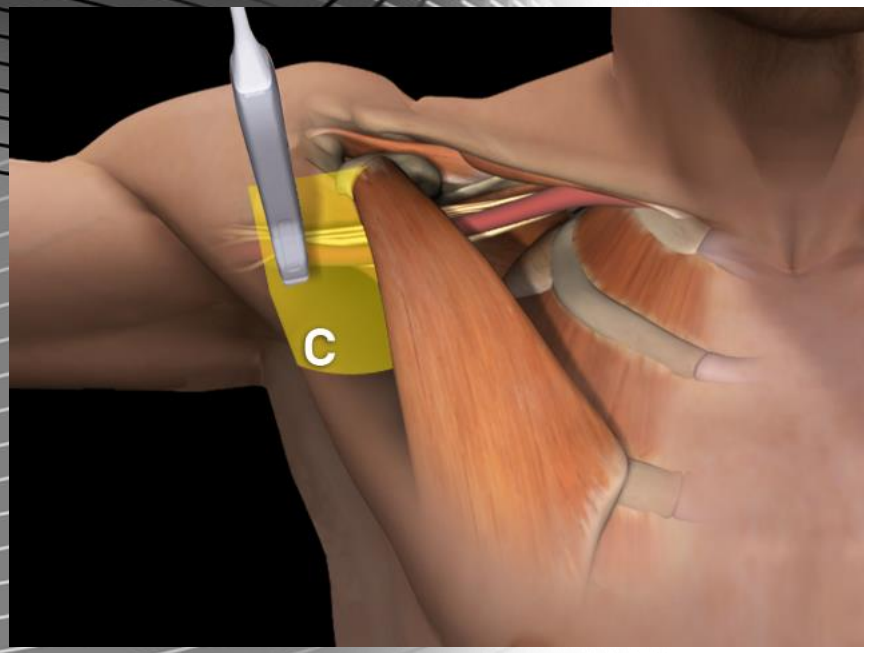

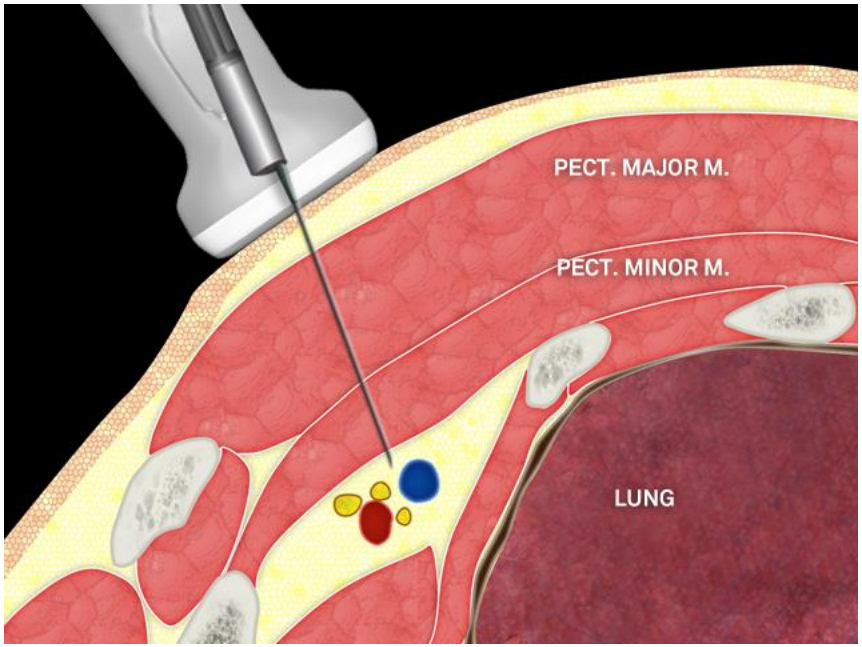

Infraclavicular Block

- Three cords
  - Lateral
  - Posterior
  - Medial
- Great deal of anatomic variation in position

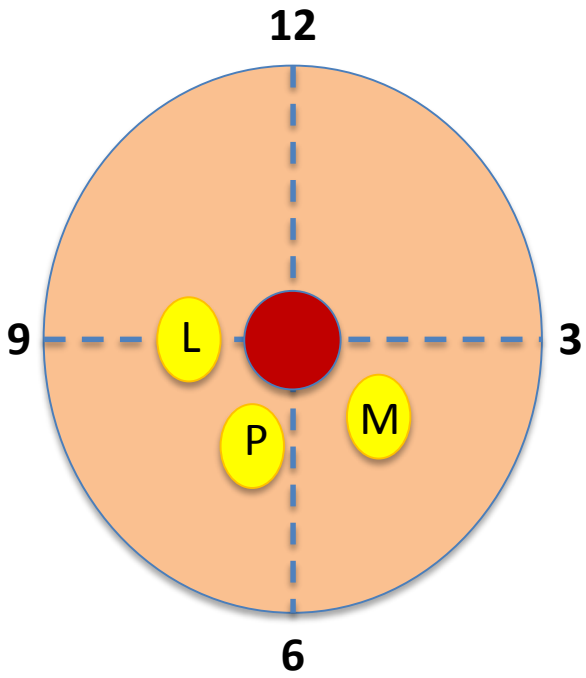

Ultrasound Infraclavicular

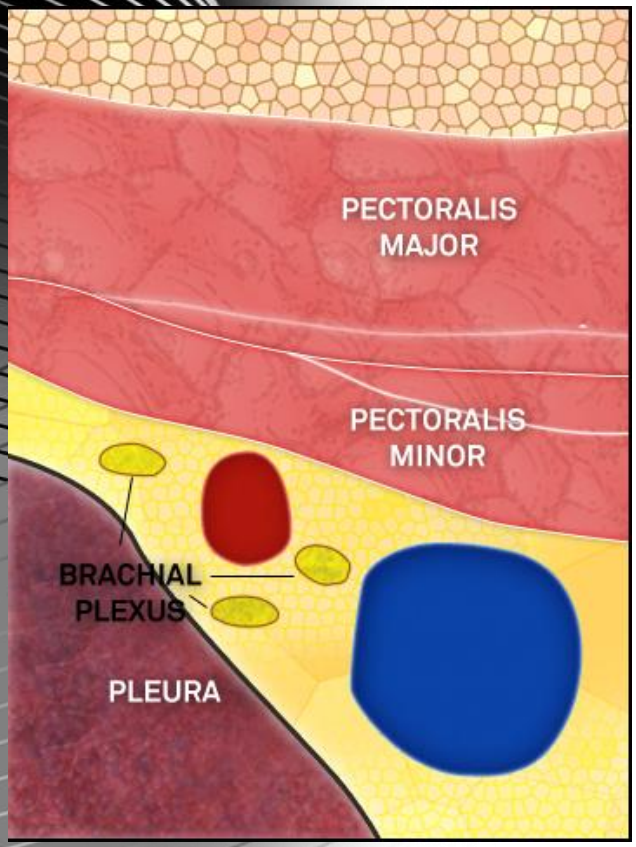

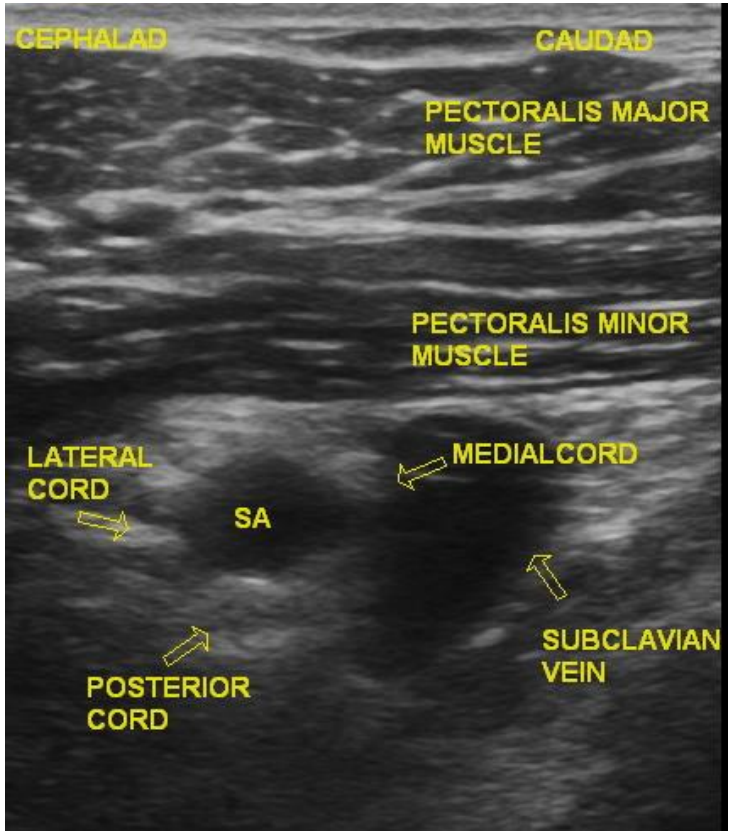

Pop Quiz

- Identify levels of brachial plexus

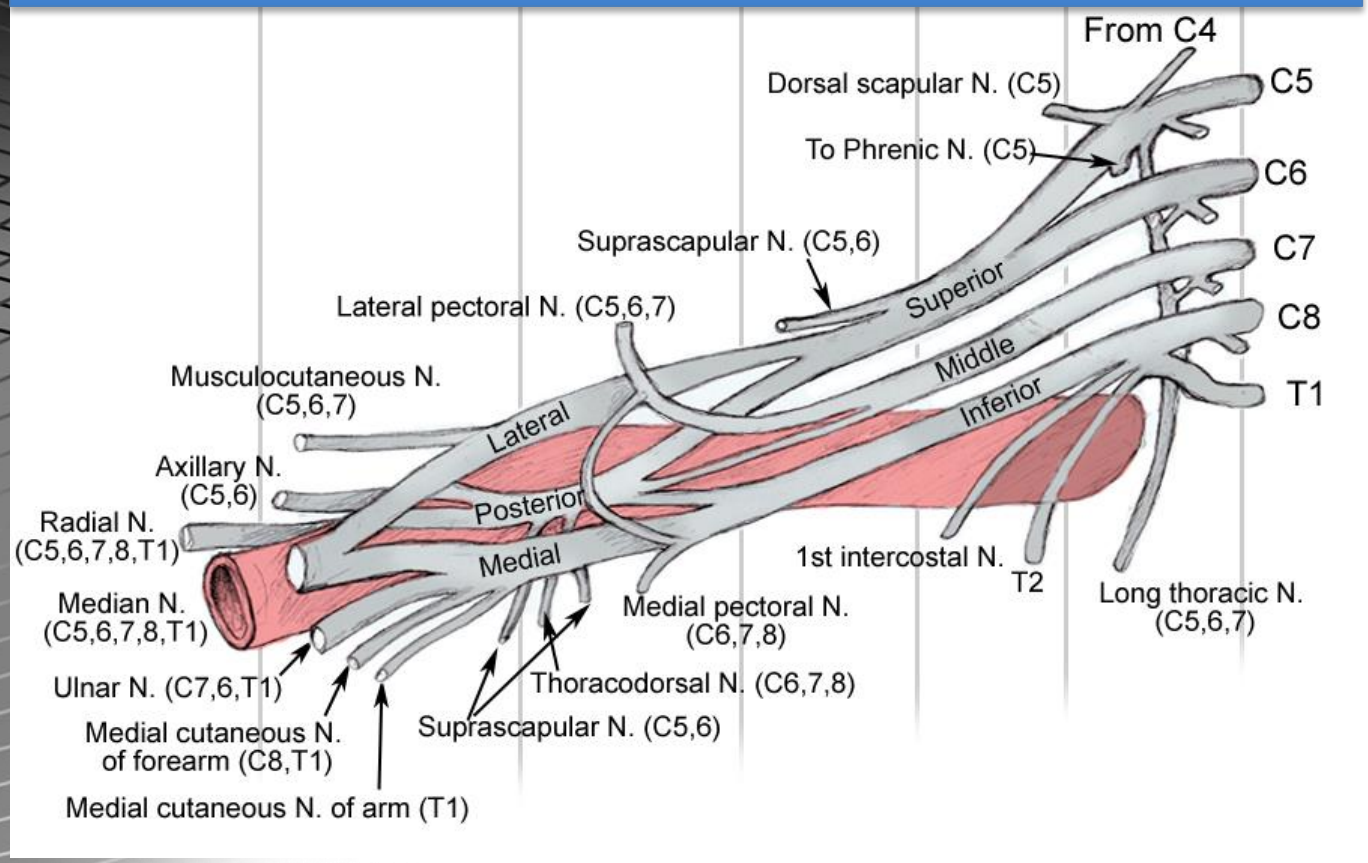

Pop Quiz

- Identify levels of brachial plexus

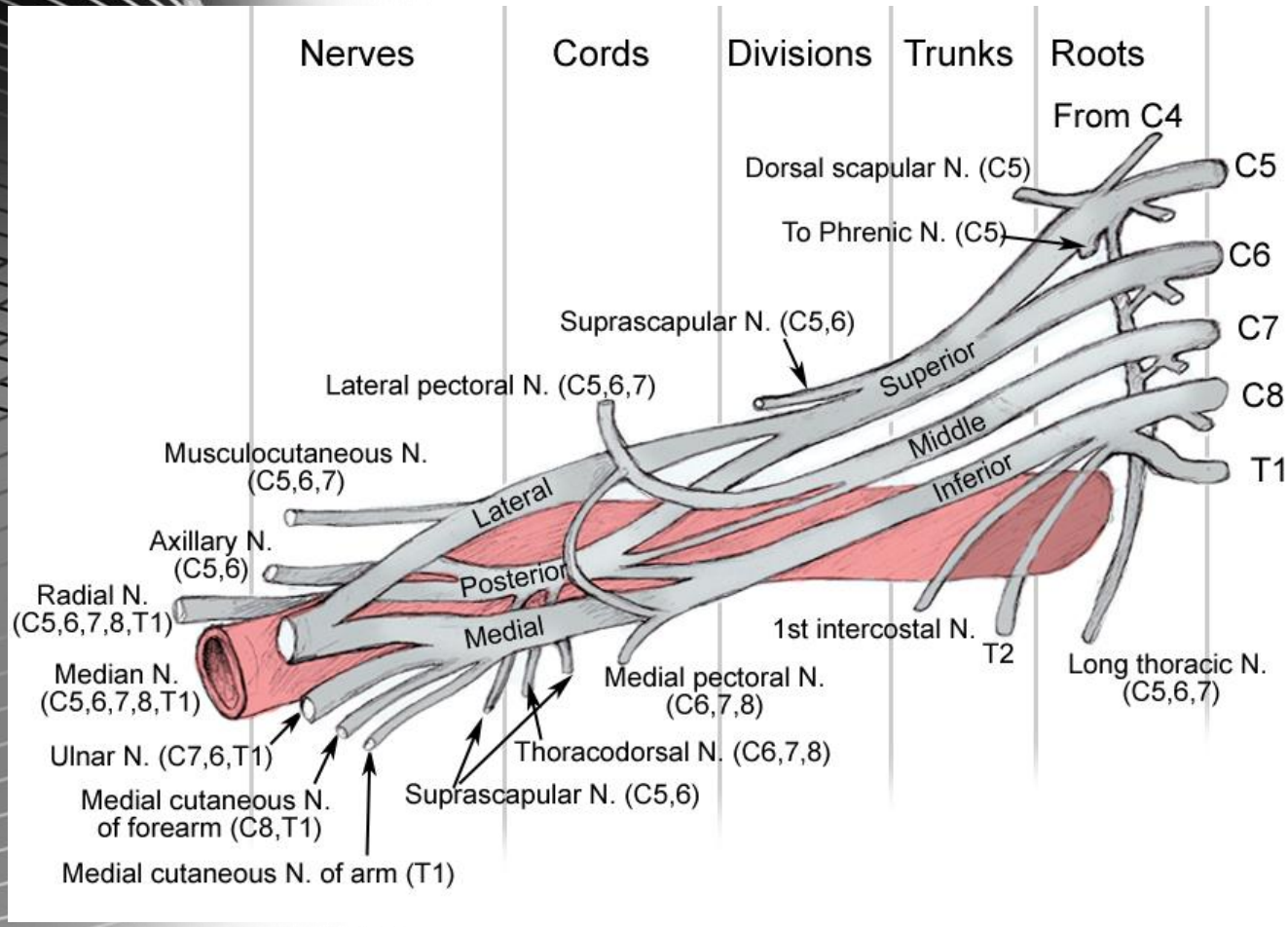

Axillary Block

- Indications: Forearm and hand surgery
- Goal: Anesthetic spread around axillary artery
- Technique: In-plane
- Notes
  - May be able to do one injection and obtain donut sign around the artery
  - More commonly requires 2-3 injections to cover all 3 nerves
  - In addition anesthetic should be injected adjacent to musculocutaneous nerve

Axillary: Terminal Branches

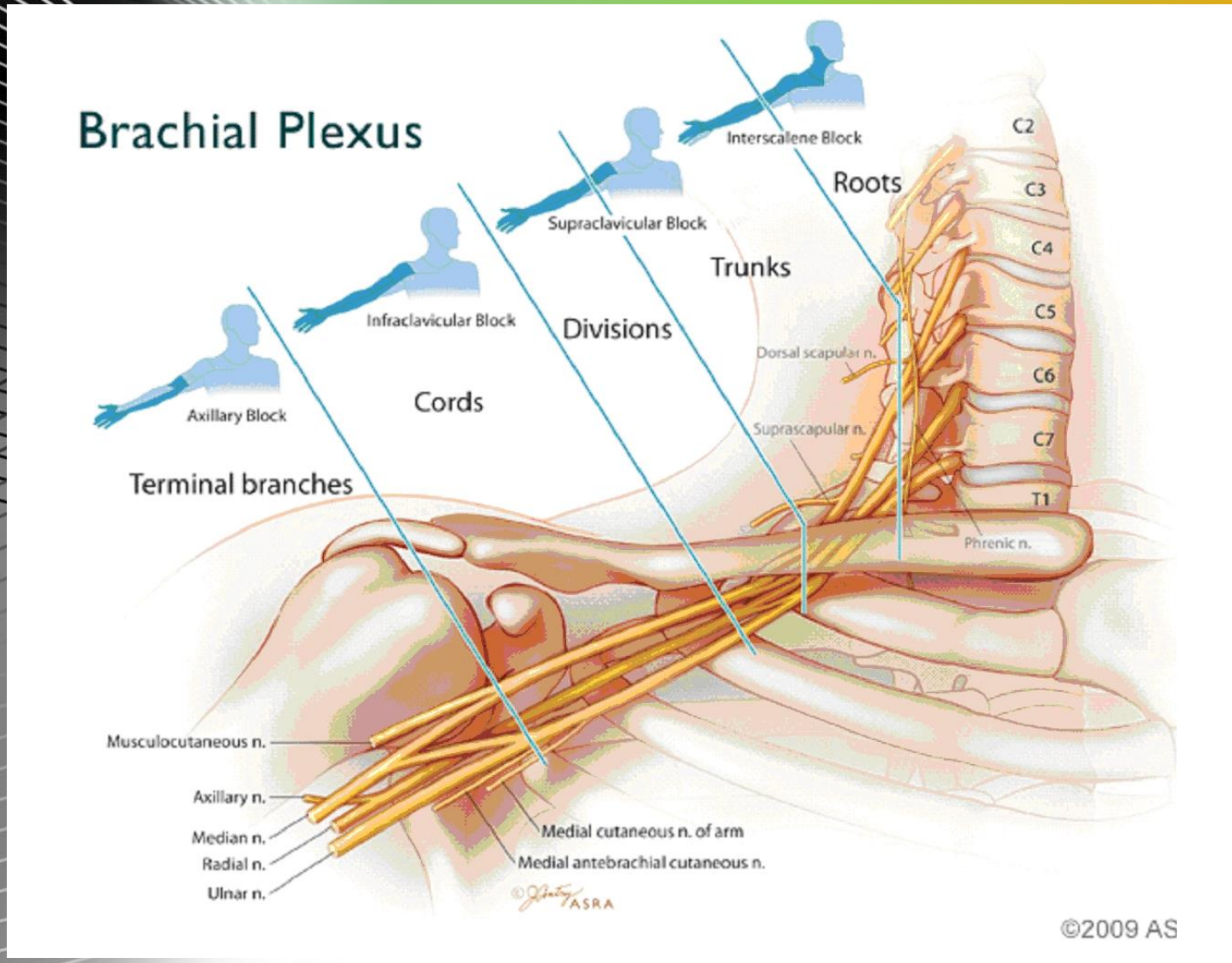

Anatomy Axillary Block

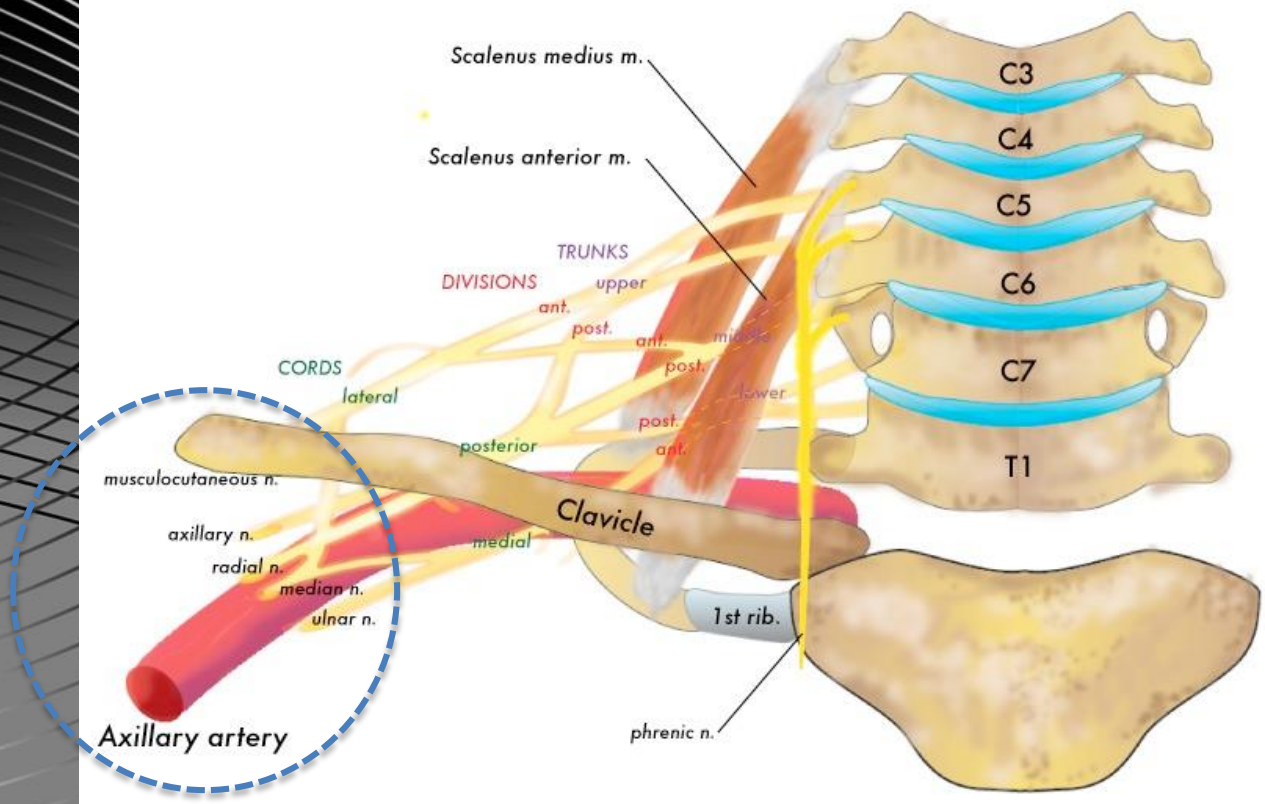

Axillary Nerve Block

- Three Nerves
  - Median
  - Ulnar
  - Radial
- Appear in variable positions around axillary artery
- Median nerve most consistent position between 12 and 2 o'clock
- Radial nerve hardest to see
- May be up to 3 large veins with plexus
- MCN ~ 3cm from axillary neurovascular bundle

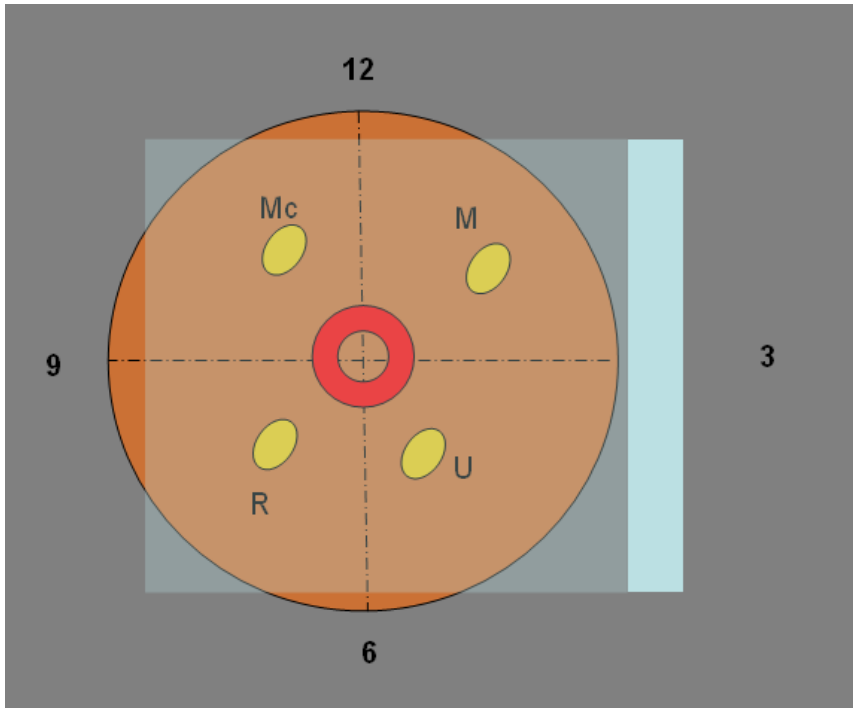

Axillary Block Transducer Position

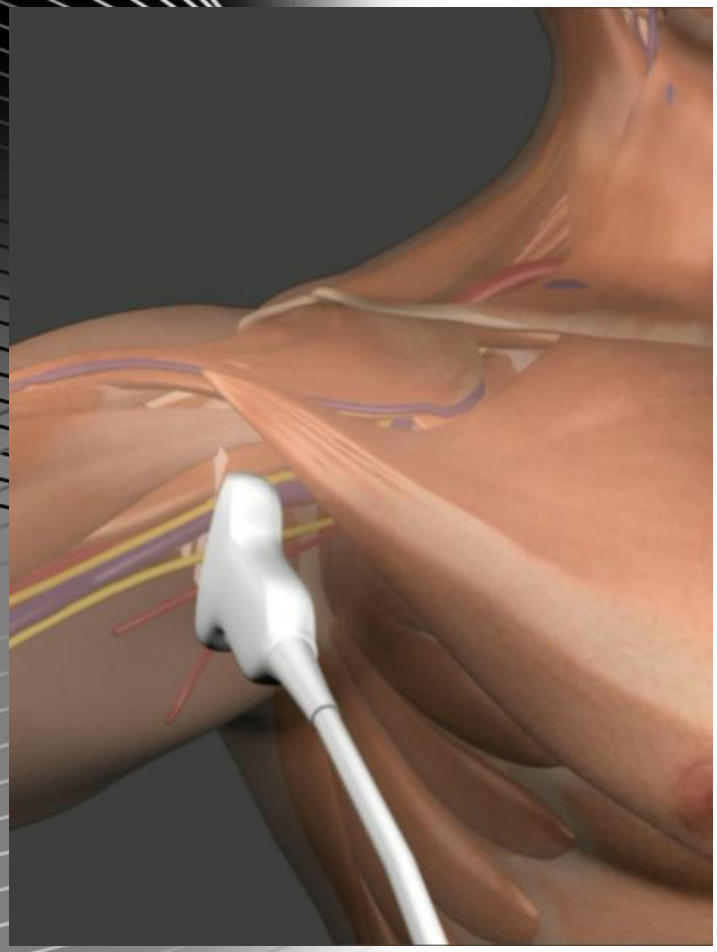

- The patient is positioned supine with the arm abducted 90 degrees and the elbow bent 90 degrees
- Transducer is placed as high as possible in the axilla
- Orientation marker directed to patient's head.

Axillary Block Transducer Position

- Transducer moved laterally over the biceps and coracobrachialis muscles. Musculocutaneous nerve between muscles as small bright circle or triangle.

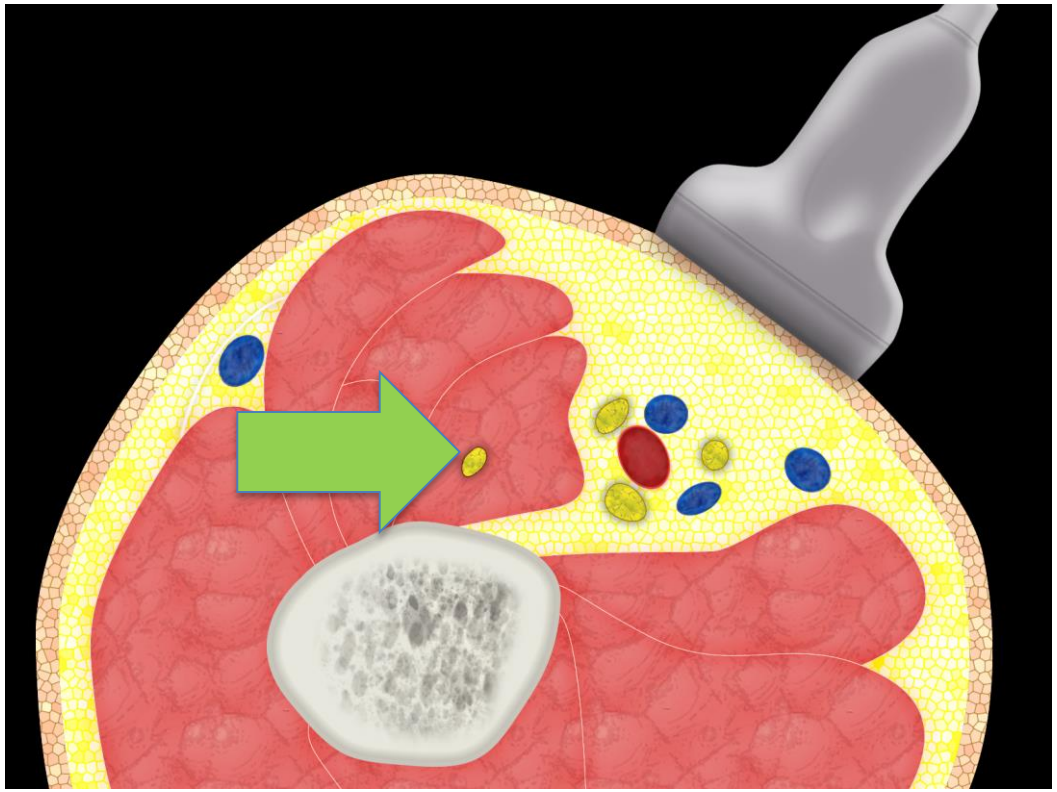

Ultrasound Axillary

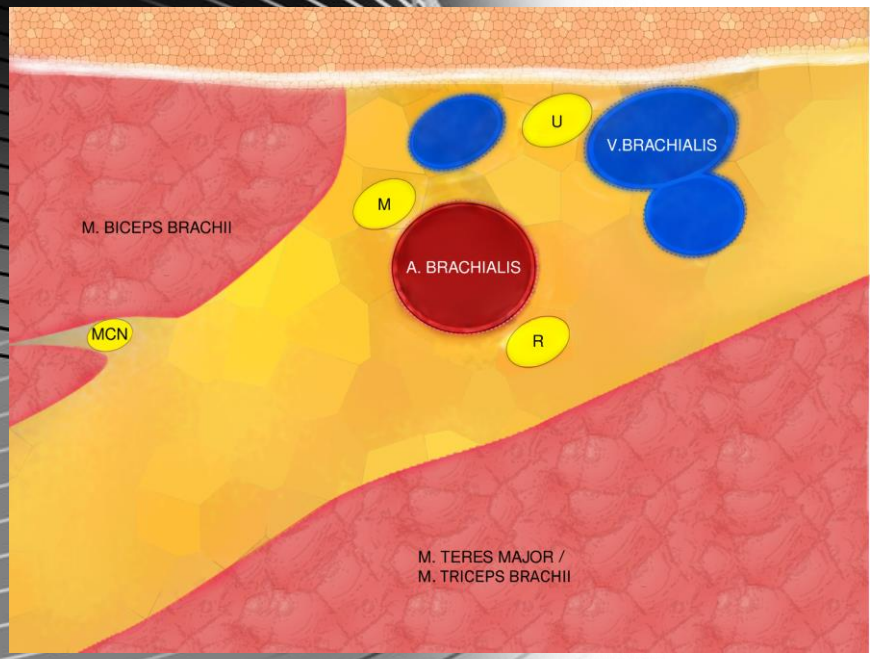

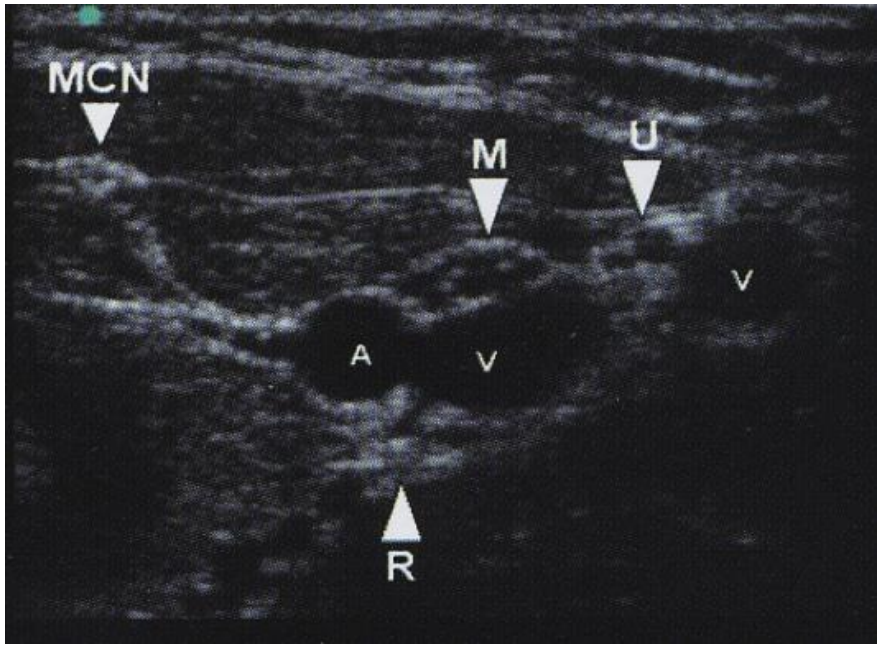

Axillary Block Transducer Position

Needle positioned 1-2cm lateral to transducer
Needle path directed through biceps muscle toward the musculocutaneous nerve.
Initial end point for the needle is immediately beside the musculocutaneous nerve.
Needle then advanced to a position immediately posterior to the artery.
Withdrawn and redirected anterior to the artery for circumferential spread

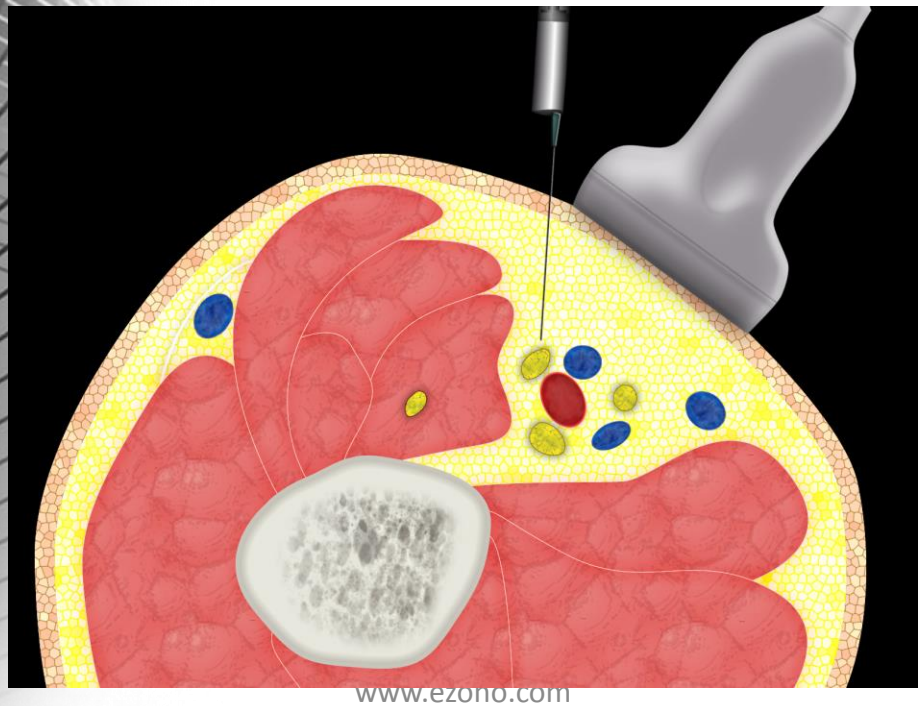

Median and Ulnar Nerve Block

- Indications: Hand surgery
- Goal: Anesthetic spread around axillary artery
- Technique: In-plane or out of plane
- Patient Position: Supine with arm externally roatated

Peripheral Nerves

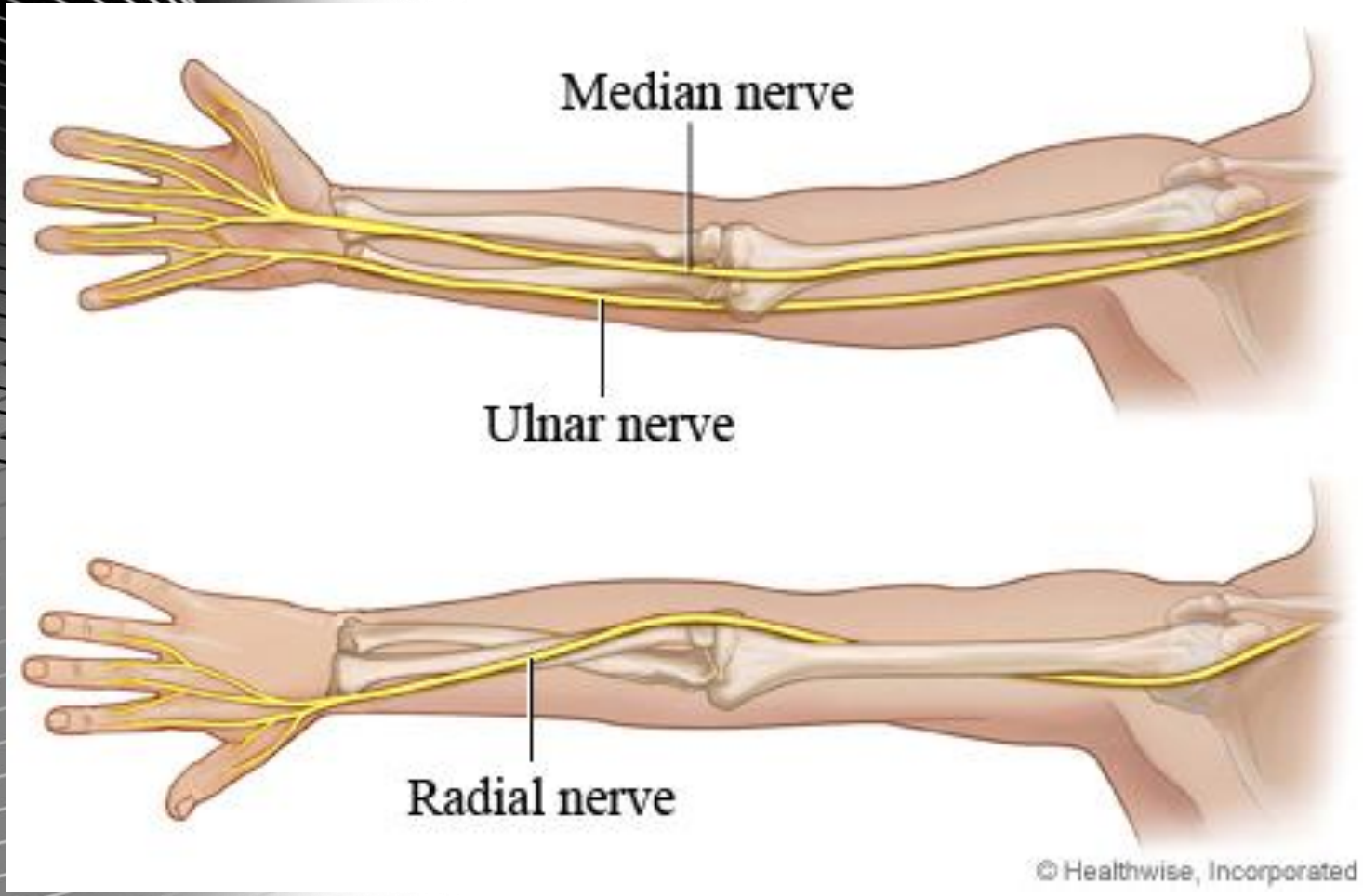

Peripheral Nerves

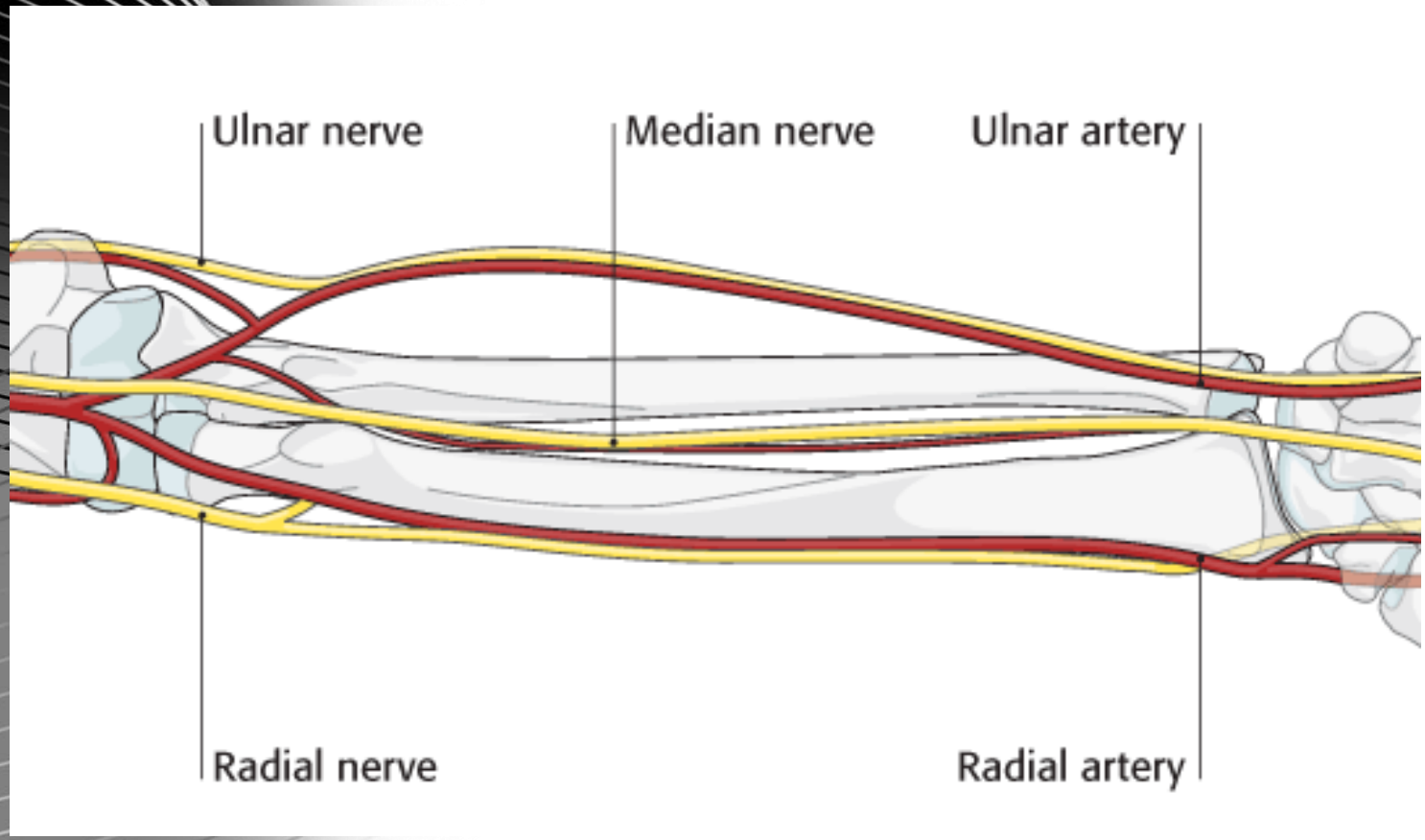

Median and Ulnar Nerve Block

- Start by identifying ulnar artery
- Ulnar nerve is oval or triangular and lies immediately medial to artery
- Trace the ulnar nerve up the forearm following the ulnar artery
- Ulnar nerve will start to separate from ulnar artery about two thirds up the forearm
- Separation allows safe placement of anesthetic

Ulnar Nerve Block

Pre-injection

Post injection

Median and Ulnar Nerve Block

- Follow the fascial plane medially to the superficial and deep flexor muscles to identify the bright hyperechoic median nerve.
- Median nerve appears as an oval or triangular bright hyperechoic structure between the muscles.

Median nerve mid forearm

Median Nerve Block

- Initial needle path to ulnar nerve
- Needle redirected laterally to the median nerve
- Nerve is medial and adjacent to brachial artery
- Approach from lateral aspect of arm

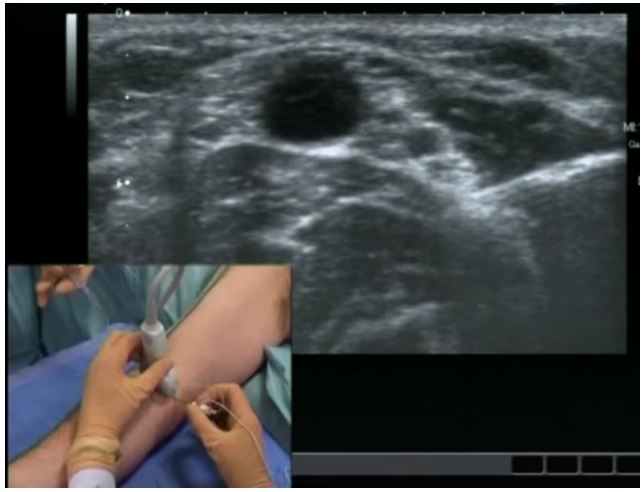

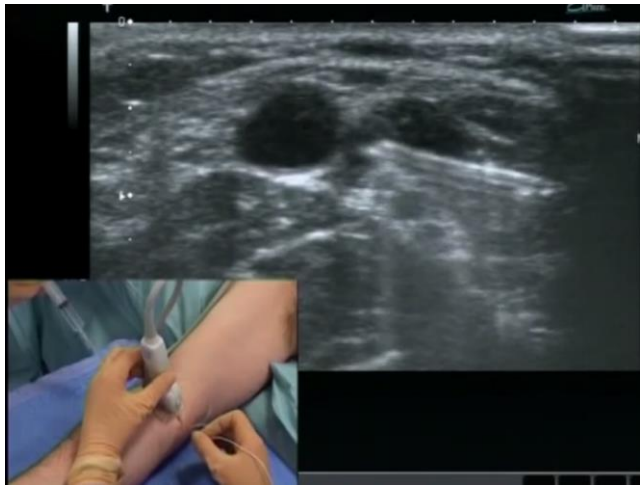

Summary

Upper Extremity Regional Nerve Blocks

- Indications
- Anatomy
- Ultrasound Technique
- Ultrasound Landmarks